

A Brief Introduction to the Evolutionary Anatomy of the Skull and Face in the Genus Homo

Una Breve Introducción a la Anatomía Evolutiva del Cráneo y Rostro del Género Homo

Carlos Alberto Mandarim-de-Lacerda

MANDARIM-DE-LACERDA, C. A. A brief introduction to the evolutionary anatomy of the skull and face in the genus Homo. *J. health med. sci.*, 5(2):107-111, 2019.

ABSTRACT: The text is indicated as a first reading to students and professionals in the biomedical area, especially those who study and teach anatomy. We reviewed some of the leading evolutionary changes that occurred in the skull and face of the hominids that preceded the modern man, documented by the fossil, geological and molecular register. It is expected to be a pleasant and easy read for the young scientist still not initiated with this knowledge, as well as for who is already studying the evolution of man.

KEY WORDS: *Homo habilis*, *Homo erectus*, *Homo neanderthalensis*, *Homo sapiens*, anatomy.

INTRODUCTION

Recently we were informed by the international media that the missing link of man's evolution, linking us to other primates, was found in Ethiopia and was named *Australopithecus ramidus*. It is dated to 4.4 million years and has a brain volume of approximately 400-500 ml (in modern man the capacity of the brain varies between 1200-2000 ml). He probably moved now erect, now over the joints of his fingers (as do orangutans, gorillas, and chimpanzees to this day). Until some new find changes the course of the story, it is decided that *A. ramidus* is our great -great -great grandfather. Its name was given already with the preconceived idea of "origin" because *ramidus* means root (Coppens, 2010).

The man is a primate. However, dissatisfied with animal status, we always try to explain our origins by using religion, science, or the mixture of the two. Conflicts aside, the fact is that we are not satisfied and probably never will be. Meanwhile, we accumulate data on the morphology of our ancestors, and little by little we embed pieces in this vast puzzle, and we penetrate a little the mist that obscures the distant past of 4 to 6 million years.

The anatomist is very close to the physical anthropologist analyzing fossil bones of the beings

of the evolutionary lineage of man. The anatomical knowledge allows us to determine if hip bones adapt to an upright position and erect walk or hand bones enable the opposition of the thumb. Also, the brain (imprinted on the inner face of the bones of the skull) may show the inferior frontal gyrus (of Broca) that is associated with the articulation of words and speech (Stein & Rowe, 1996).

That is why the anatomist is often called upon to participate in fossil analysis. In contact with researchers from the *Musée de l'Homme*, in Paris, I have always seen close cooperation between anatomists and anthropologists. This association is evident in works such as "*Étude des restes fossiles des pieds des premiers hominidés: Australopithecus et Homo habilis. Essai d'interprétation de leur mode de locomotion*" (Study of the fossil remains of the feet of the first hominids: *Australopithecus* and *Homo habilis*. Test of interpretation of their mode of locomotion) (Deloison, 1993).

We can identify the significant evolutionary trends of the human lineage by comparing the fossil records with the living primates, including man evaluating the consequences of our evolutionary process and predict future changes.

Molecular biology is also a powerful tool for investigating the process of human evolution. Recent studies using molecular genetics have made it possible to group fossils in one or other evolutionary direction, showing how close or how far apart they are.

The Evolutionary Tendency of the Skull

The older the fossil in the human lineage, the smaller the space reserved for the brain as the evolution of the skull is associated with the tendency of brain enlargement concomitantly with the reduction of the face projection and the thinning of the masticatory muscles. Older fossils show a marked sagittal crest that served to insert a potent temporal muscle placed in a proportionally sizeable temporal fossa.

The foramen magnum was more dorsal because the atlanto-occipital joint served the backbone of a being whose posture was not perfectly erect, at least not permanently. As a result, there was virtually no space in the cranial cavity behind the foramen magnum. The crests and nuchal lines were coarse and very developed where they inserted the powerful muscles of the nape. So, it can be explained by the unfavorable biomechanical arrangement between the spine and the head, which hung forward and down more than presently. Figure 1 shows the cranial cavity gain (then brain) with the more ventral position of the foramen magnum (Aiello & Dean, 1990).

From the biomechanical point of view, the balance of the head obeys a class 1 lever (which has the pivot - the atlanto-occipital joint - placed between the 'force' - muscles of back - and 'resistance' - head weight) (Fig. 2).

In this system, the 'force' increases when the foramen magnum is placed more dorsal (shortening the 'force' length), requiring more powerful neck muscles to maintain the balance of the head. As we approach the modern man, who has the most ventral foramen of all primates, the 'force' length extends and, therefore, the crests and nuchal lines thin indicating that the neck muscles are losing importance.

Still speaking of the fossils of the human lineage, we observed a strong excavation in the frontal region with a consequent supraorbital protrusion that steals space of the cranial cavity. Such anatomical formation might be found even in *Homo neanderthalensis* (which lived about 200 thousand years ago - which is considered recent) (Patou-Mathis, 2010). The supraorbital protrusion gave a rough and coarse

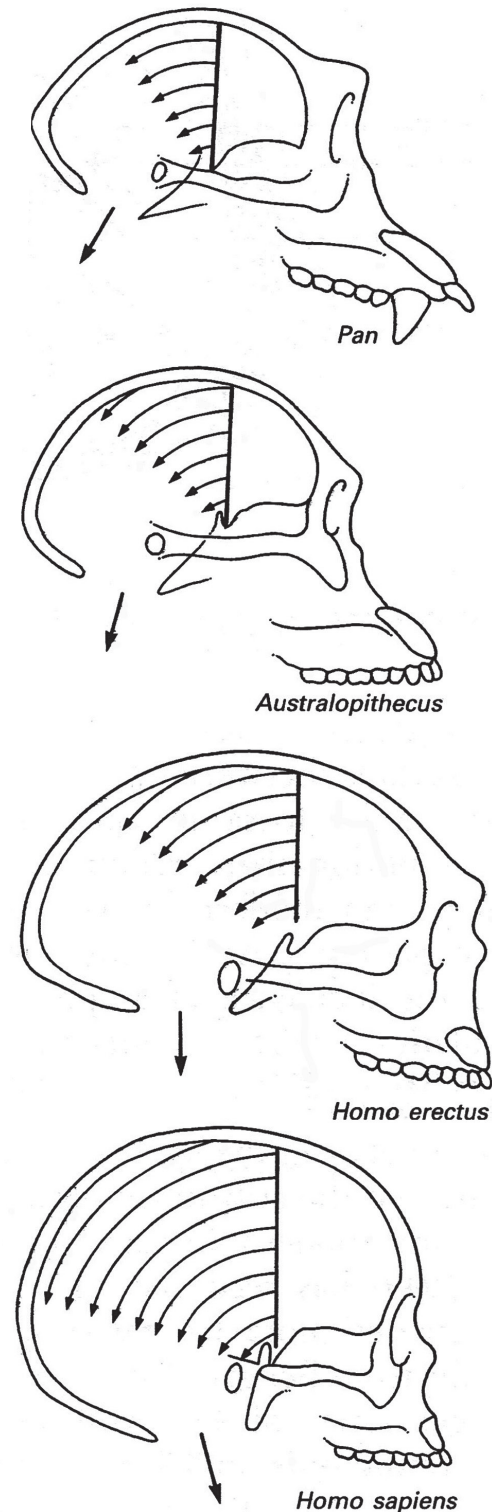


Fig. 1. Increase of the cranial cavity from the chimpanzee (Pan genus) to modern man (below) passing through the hominid ancestors (*Australopithecus* and *Homo erectus*). The arrow indicates the position of the atlanto-occipital joint and the location of the vertebral column.

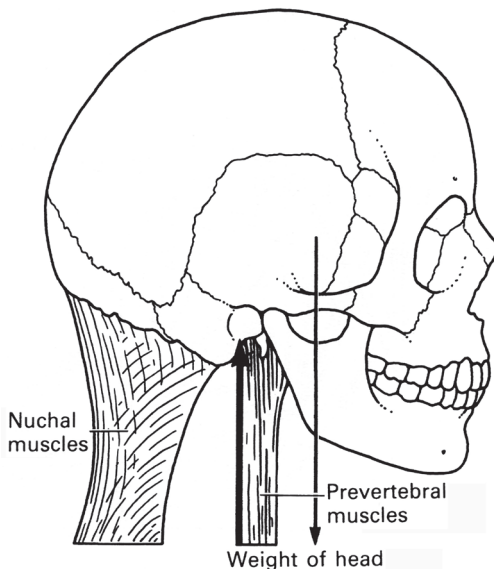


Fig. 2. Biomechanics of head support. The support occurs at the atlanto-occipital joint.

appearance to the face, but modern man (*H. sapiens*) shows a forehead ending at the upper edge of the orbit (Campbell, 1998).

Thus, the cranial brain cavity was smaller in the most primitive hominids than in modern man. Throughout the evolution of man, the brain cavity grew because of anatomical evolutionary changes possibly linked to an upright position with free hands. The primary changes we can identify allowing a more magnificent brain are:

- a. An increase in the occipital area, because of the forward displacement of the foramen magnum. In the brain's occipital lobe of the modern man there are functions related to vision (has there been an improvement in stereoscopic vision?).
- b. An increase in the parietal-temporal area, due to the "pumping" out of the skullcap, simultaneously with the reduction of the temporal muscle (because of biomechanical improvement in chewing) (we switched muscle by brain!).
- c. An increase in the frontal area, due to the "pumping" out of the supraorbital excavation with thinning of the supraorbital edge. The frontal lobe's ventral part in modern man is functionally related to behavior and personality.

The groove for the middle meningeal artery in the inner part of the skull bones is apparent in all fossils, which denotes a growing brain. However, the bone depression usually caused by the bulging of the

inferior frontal gyrus (Broca's area) only appears in the most recent fossils (since *Homo habilis* - 3 millions of years), which might suggest some verbal articulation in these hominids (Stein & Rowe).

The Evolutionary Tendency of the Face

The face is diminishing in human evolution. The older the fossils of the human lineage, the more protruding is the face (Fig. 3). The biomechanical balance of mastication corresponds on a class 3 lever (levers are formed by muscles and bones acting together. A lever is a rigid rod - usually a length of bone - that turns about a pivot - usually a joint). The purpose of studying levers that exist in the human body is that the levers are simple machines capable of mechanical advantage (a small force applied to the lever can move a larger weight, or facilitate its displacement, even without having a mechanical advantage).

The central facial pivot is the temporomandibular joint (TMJ), the 'resistance' remains in the contact of

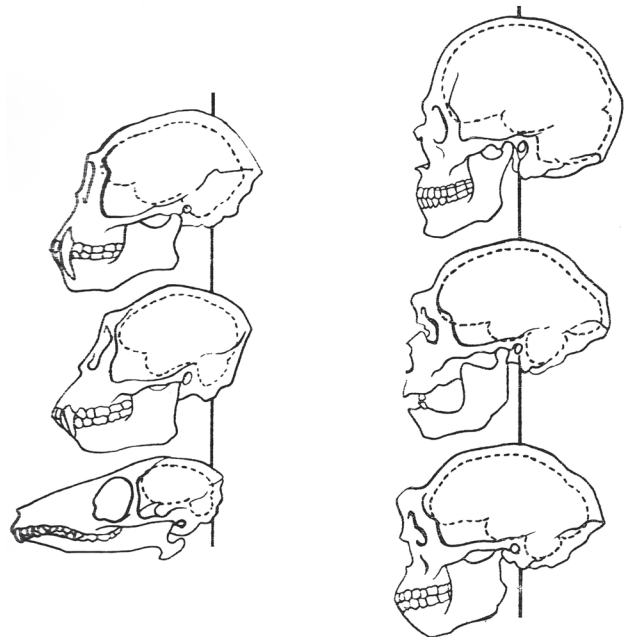


Fig. 3. Skulls of various primates aligned upon the point on which they pivot on the spine, the occipital condyles. The center of gravity moves back (from the lower to the higher primates - the brain expands, the jaws recede). Left sequence from bottom to top: *Tupaia*, *Cercopithecus*, *Hylobates*. Right sequence from bottom to top: *Homo erectus*, *Homo neanderthalensis*, *Homo sapiens* (Dubrul & Sicher, 1954; Campbell, 1998).

the teeth, and the 'force' is exerted on the mandible by the action of the masticatory muscles. With the more advanced face (usually in animals with muzzles

and older hominids), the 'resistance distance' of the TMJ lever is more significant, which needs more 'force' from the masticatory muscles. The need for more powerful muscles to raise the mandible is linked with the existence of the sagittal crest, the sizeable temporal fossa, and thicker ramus of the mandible in earlier hominids. The sagittal crest and a concave temporal fossa are necessary to adapt the powerful temporal muscle (stealing area of the skull cavity), while a thicker ramus of the mandible is caused by the denser muscles masseter (lateral) and medial pterygoid (medial).

The 'resistance' is more distant from the pivot than the 'force' in Class 3 lever (in this case there is no mechanical advantage because the 'force' is higher than the 'resistance'). However, this disadvantage is compensated with a more significant movement (Campbell).

The more protruding, the more oval or elliptical face is the occlusal line (Fig. 4). In modern man this line is almost circular, which reduces the space reserved for teeth, hence the tendency in decreasing the number of teeth, especially the third molar (Condemi & Savatier, 2018). Also, in the human lineage, there was a reduction of the size of the teeth, mainly of the

canine that does not exceed much more the occlusal line. In other current primates and the hominids, the older the fossil, the more prominent is the canine, causing a space in the opposing dental arch, called canine (or simian) diastema (Aiello & Dean).

The mental protuberance (chin or gnathion craniometric point), a ventral protrusion of the midline mandible, appeared recently. The jaw of the modern man is the only one to present "chin" (mental protuberance is observed only from the fossil of *H. neanderthalensis*, the fossils of older hominids does not have a chin). The growth of the chin in modern humans has been active since fetal development. The mandibular growth in human fetuses showed positive allometry for the dimensions gonion (angle of mandible)-gnathion and symphyseal height, in comparison with other prenatal mandibular dimensions (Mandarim-de-Lacerda & Alves, 1992).

In general, in the same gender the more modern, the thinner the face is. The cavities between the face and the skull - orbits, nose, mouth - are smaller and less apparent. Zygomatic bones are also relatively reduced in modern man compared to other hominids. Therefore, the modern human has a smooth face in comparison with older hominids.

The jaw is smaller and less robust in modern man. Mauer's jaw (European *Homo erectus* - about one million years ago) has large teeth and a much broader and thicker ramus of mandible than modern man. Also, the robust Mauer's coronoid process indicates insertion of a powerful temporal muscle; the excessive roughness observed in the ramus of the mandible also suggests the insertion of strong muscles masseter and medial pterygoid (Campbell).

Final remarks

The evolution of man has not stopped (neither of man nor all other living beings). What we see today is a 'photograph' of man in the present conditions. Evolutionary forces are acting and adapting (modifying) according to the laws of natural selection. What we have presented in this brief review is what we have learned by studying hominid fossils in comparison to the anatomy of modern man, which gives us the opportunity to have an evolutionary perspective on the anatomy of the human skull and face. This understanding helps us position ourselves as participants in the show of life on Earth.

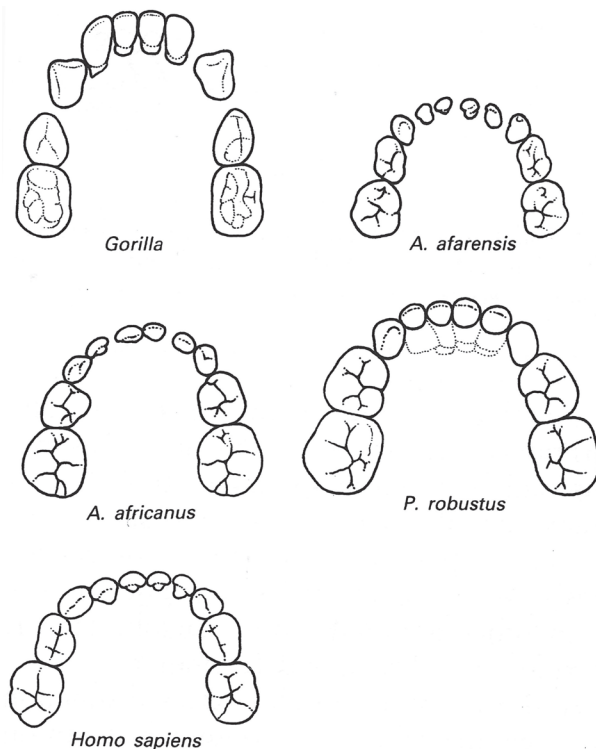


Fig. 4. Comparison of the dental arch anatomy: gorilla, some fossil hominids and the modern man.

ACKNOWLEDGMENTS

The author is a Titular Member of the National Academy of Medicine of Brazil (<http://www.anm.org.br/>), and Foreign Associate Member of the National Academy of Medicine of France (<http://www.academie-medecine.fr/>), and is supported by Conselho Nacional de Desenvolvimento Científico e Tecnológico (Brazil) (CNPq, Grant No 302.920/2016-1), and Fundação Carlos Chagas Filho de Amparo à Pesquisa do Estado do Rio de Janeiro (Faperj, Grant No E-26/202.935/2017). These agencies had no interference in the accomplishment and submission of the manuscript.

Corresponding author:
Carlos Alberto Mandarim-de-Lacerda
Universidade do Estado do Rio de Janeiro
Centro Biomédico
Rio de Janeiro
BRASIL

Phone: +55 21 2868 8316
Fax: +55 21 2868 8033

Email : mandarim@uerj.br

Received: 23-03-2019
Accepted: 02-04-2019

MANDARIM-DE-LACERDA, C. A. Una breve introducción a la anatomía evolutiva del cráneo y rostro del género Homo. *J. health med. sci.*, 5(2):107-111, 2019.

RESUMEN: El artículo está indicado como primera lectura para estudiantes y profesionales del área biomédica, especialmente aquellos que estudian y enseñan anatomía. Revisamos algunos de los principales cambios evolutivos que ocurrieron en el cráneo y rostro de los homínidos que precedieron al hombre moderno, documentados por el registro fósil, geológico y molecular. Se espera que sea una lectura agradable y fácil para el joven científico que aún no ha recibido este conocimiento, así como para quien ya está estudiando la evolución del hombre.

PALABRAS CLAVE: *Homo habilis*, *Homo erectus*, *Homo neanderthalensis*, *Homo sapiens*, anatomía.

REFERENCES

- Aiello, L. C. & Dean, C. *An introduction to human evolutionary anatomy*. London, Academic Press (Harcourt Brace Jovanovich, Pu.), 1990. p. 596.
- Campbell, B. G. *Human evolution. An introduction to man's adaptations*, 4th ed. London & New York, Routledge, Taylor & Francis Group, 1998. p. 284 .
- Condemi, S. & Savatier, F. *Dernieres nouvelles de sapiens*. Paris, Flammarion, 2018. p. 155 .
- Coppens, Y. *L'histoire de l'homme: 22 ans d'amphi au college de france (1983-2005)*. Paris, Odile Jacob, 2010. p. 246 .
- Deloison, Y. Etude des restes fossiles des pieds des premiers hominides : *australopithecus* et *Homo habilis*. éssai d'interpretation de leurs mode de locomotion. Thesis. Paris, Université René Descartes, 1993. p.782.
- DuBrul, L. & Sicher, H. *The adaptative chin (American Lectures Series No. 180)*. Springfield, Charles Thomas, 1954. p. 97.
- Mandarim-de-Lacerda, C. A. & Alves, M. U. Human mandibular prenatal growth: bivariate and multivariate growth allometry comparing different mandibular dimensions. *Anat. Embryol. (Berl)*, 186: 537-41, 1992.
- Patou-Mathis, M. *Neanderthal, une autre humanité*. Paris, Perrin, 2010. p. 365.
- Stein, P. L. & Rowe, B. M. *Physical anthropology*. 6th ed. New York, McGraw-Hill Co. Inc. 1996. p. 586.